Percutaneous Renal Biopsies and Hemorrhage in Multiple Myeloma

M. Rodgers, R. Baber, W. Culp, R. Reinholtz, J. Matchett, T. McCowan

University of Arkansas for Medical Sciences and Myeloma Institute for Research and Therapy Little Rock, AR

Purpose:

Review our experience with hemorrhage in CT guided renal biopsy in Multiple Myeloma and non Myeloma patients.

Background:

Renal biopsy is commonly done in patients with increased bleeding risks due to chronic renal disease or multiple myeloma, (MM). Multiple myeloma causes renal impairment by amyloid deposition and immunoglobulin deposition, and it also can be the effect of the MM therapies. Renal biopsy is required to differentiate between these processes.
Biopsy procedures are associated with increased risk of bleeding since MM therapy often causes thrombocytopenia and anemia. In addition, MM elevates bleeding risk by unique derangements of hemostasis associated with B-cell disorders. Excessive MM bleeding can be due to:

- Low Factor VIII, IX, X and/or vitamin K function
- Intravascular coagulopathy
- Amyloid deposition, which makes tissues fragile
- Compromised fibrin function

As a result, 3% of MM patients die from bleeding and 40% of amyloid patients have clinically significant bleeding in the course of their disease.

To best visualize and control needle placement, CT-guided biopsy is the technique of choice and the choice of the MM service for all renal biopsies. It is also used in select nephrology cases where ultrasound guidance may be difficult or bleeding risks are especially elevated.

Figure 1. **Renal Vascularity:** The most difficult to control and dangerous bleeding comes from encounters with renal artery branches. The largest and most likely to bleed persistently are concentrated in the central half of the kidney, close to the collecting system. Veins are also central in location, but rarely bleed excessively. A tangential needle placement in the peripheral one third of the kidney (arrow) can miss the largest arteries and decrease episodes of bleeding.

Used with permission: R Uflacker; Atlas of Vascular Anatomy, an Angiographic Approach. 1997

Figure 1

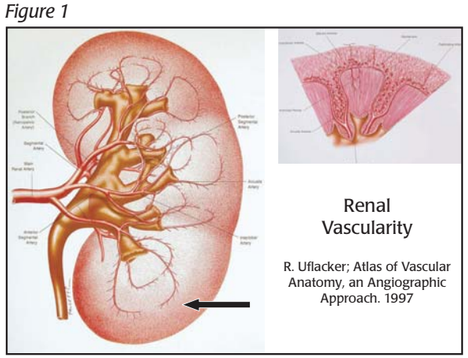

Presented March 29, 2004, Society of Interventional Radiology Annual Scientific Meeting, Phoenix. Abstract: JVIR 2004; 15:S203

Methods:

This is a retrospective review of all CT-guided renal biopsies for non mass lesions from 2001 through 2003. We recorded the following:

- Clinical outcomes
- Locations of needles
- Needle size, and number of passes
- Visible hemorrhage, 0 to 4 scale, as judged by 3 blinded radiologists who then conferred and reached consensus

Grades of Bleeding
Grades are judged by the greatest thickness of bleeding seen on available CT slices. Volume was not directly assessed since the full extent was not usually included in the saved images available for review.

- Grade 0, none seen
- Grade 1, < 1 cm
- Grade 2, 1 to 2 cm
- Grade 3, 2 to 3 cm
- Grade 4, > 3 cm or distant

Figure 2: CT images at placement and 2 minutes after needle removal show grade 2 bleeding from a tangential 18 g biopsy of the lower pole of the right kidney. Note the absence of renal pelvic structures indicating a pole site of biopsy. A thin string of blood extends away from the renal puncture site about 2 cm (arrow). The patient was asymptomatic.

Figure 2

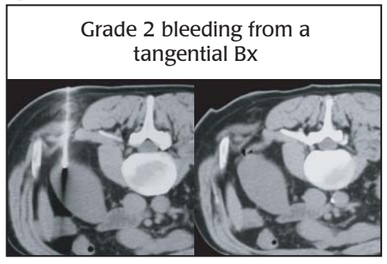

Figure 3: CT images at placement, just after biopsy, and 5 minutes later show grade 4 bleeding from a central placement in the lower pole of the left kidney. An 18 g needle was used for three cores. Bleeding persisted and eventually led to angiographic embolization of the bleeding arterial branch. However, the patient eventually died during this hospitalization from related problems.

Figure 3

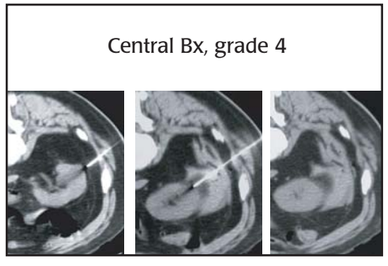

Results:

Fifty four consecutive cases, 30 MM and 24 non-MM, were acquired from 2001 - 2003.
All had correction of INR to <1.6 and platelets to >75,000.
Needles included 49 18 g ASAP, two 15 g ASAP, and three 20 g Turner needles.
All had adequate samples, but the Turners were marginal and are no longer used.

- Overall mean hematoma score:

MM 1.57 vs non-MM 1.0, p = 0.08, a strong tendency for more bleeding in MM
Central 1.62 vs Tangential 1.12, p = 0.14, tends to more bleeding centrally
Middle 1.2 vs lower pole 1.54, p = 0.48, NS

- MM vs. non-MM scores

Central scores:
MM 1.75 vs non-MM 1.44, p = 0.61, NS
Tangential scores:
MM 1.44 vs non-MM 0.73, p = 0.05, significantly different
Moderate or severe bleeding, grade 3 or 4; MM 23% vs non MM 8%, NS

- Complications
- **Minor**
- Additional imaging, 6
- Outpatient hematuria, 1
- **Major**
- Transfusions, 3 (2 MM and 1 non MM)
- Arterial embolization and death, 1 (MM)
- Additional hospitalization for hematuria, 1

Figure 4: CT of the "Ideal Tangential Approach" placed low in the lower pole of the right kidney. Such placement is associated with decreased bleeding. However, even perfectly placed needles of moderate size may cause severe bleeding in a particular patient. All patients must have coagulation factors optimized and be watched several hours following the procedure for signs of bleeding.

Figure 4

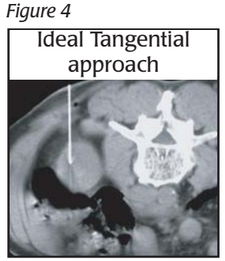

Discussion:

- All patients getting renal biopsies, either with or without MM, are likely to have bleeding problems. This is the primary risk of this procedure and makes correction of the coagulation factors most important prior to biopsy.
- Precision of needle placement **does** make a difference.
- All categories tend toward more bleeding with MM than in non-MM.
- Central biopsies (where larger vessels are encountered) show an increased bleeding tendency.
- Safest MM group is the Tangential biopsy group.
- Safest group of all is non-MM Tangential biopsy group which is significantly safer than MM.
- Alternative techniques including transjugular venous and blunt tipped needle techniques have been reported and might be worth developing for very high risk patients.

Conclusion:

- Renal biopsies in multiple myeloma tend to bleed more often and to a greater extent than non-MM cases.
- Tangential biopsy in non-MM patients causes statistically less bleeding than in MM patients.
- CT guided tangential needle placement is precise, tends to produce less bleeding, and should be the standard approach for renal biopsy, especially in high risk patients.

References:

- Y Hoshino, K Hatake, K Muroi, et al. Bleeding tendency caused by the deposit of amyloid substance in the perivascular region. Internal Medicine 1993; 32:879-881
- J Glaspy. Hemostatic abnormalities in multiple myleoma and related disorders. Hemotology/ oncology Clinics of North America 1992; 6:1301-1314
- E Angtuaco, A Fassas, R Walker, R Sethi, B Barlogie. Multiple myeloma: clinical review and diagnostic imaging. Radiology 2004; 231:11-23